

## IMAGING GAMUT

## Scintigraphic pattern of oncogenic hypophosphataemic osteomalacia mimicking bone metastases

Alshaima Al-Shammari\*, Khadeija Al-Owaid, Rasha Ashkanani, Sharjeel Usmani

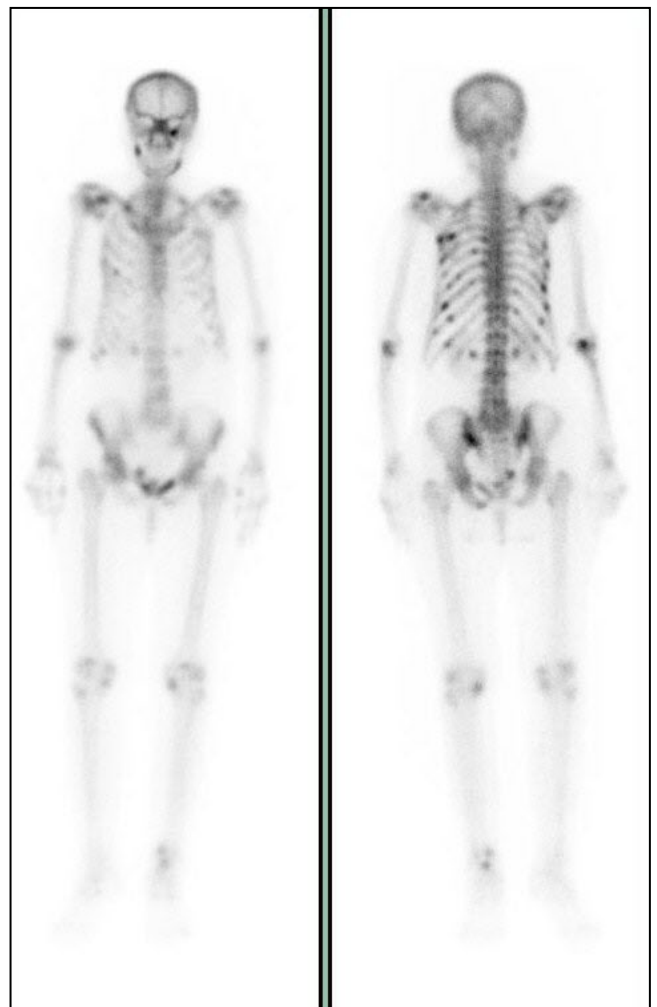
Department of Nuclear Medicine,  
Mubarak Al-Kabeer Hospital, Kuwait

**Key words:** *Oncogenic hypophosphataemic osteomalacia, bone scan, bone metastases.*

**Background** A 61-year-old lady was admitted to the hospital following severe progressive generalized debilitating musculoskeletal pain and high alkaline phosphatase at 500 IU/L (normal range 26-88 IU/L). The patient was referred to the nuclear medicine department to investigate the possibility of Paget's disease versus bone metastases.

**Procedure** A delayed 3-hour whole-body bone scan with spot views over the chest and skull were acquired following 814 MBq <sup>99m</sup>Tc-HDP intravenous injection.

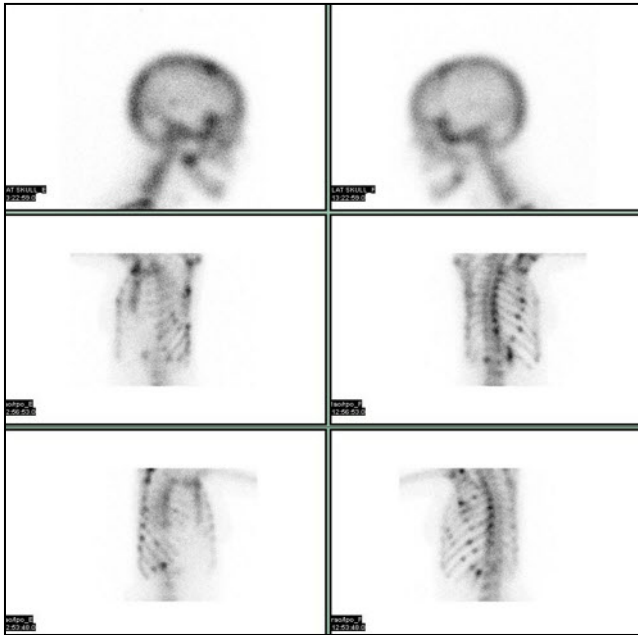
**Findings** The whole-body bone scan and spot views over the skull and chest (Figures 1 & 2) showed multiple foci of intense increased radiotracer uptake involving the skull, mandible, multiple ribs bilaterally, with further hot-spots in the the pelvis and possibly in the spine. Degenerative changes were seen in several joints including the shoulders, the knees and the left ankle. The pattern seen in



**Figure 1** Whole-body bone scan images (see text)

**\*Correspondence**

Al-Shaima Al-Shammari  
Mubarak Al-kabeer Hospital  
PO Box 24923,  
Safat, Kuwait  
Tel: +965-99674017



**Figure 2** Planar bone scan spot view images (see text)

in the ribs and skull was reported as multiple insufficiency fractures and/or bone metastases. Additional investigations revealed a low serum phosphate of 0.5 (normal range: 0.8-1.4 mmol/L), and low serum calcium levels of 2.0 mmol/L (normal range: 2.2-2.6 mmol/L). Parathyroid hormone level was normal. The active form of vitamin D1, 25 (OH) 2D3 (Calcitriol) was also within normal range. Diagnostic CT images of the chest, abdomen and pelvis were normal. Patient was treated with oral Calcitriol and her symptoms improved, and follow-up of the patient for one year with diagnostic CT did not show any evidence of a primary tumour.

In cases of oncogenic hypophosphataemic osteomalacia, the bone scan appearance may mimic bone metastases. This condition is classified as a paraneoplastic syndrome in that the neoplasm is often of a limited clinical significance apart from its impact on the musculoskeletal system. Tumours often remain unidentified for years following the diagnosis of hypophosphataemic osteomalacia and the management in such cases is phosphate and calcitriol and long-term surveillance.

**Conclusions** In cases of oncogenic hypophosphataemic osteomalacia, the bone scan appearance may mimic bone metastases as shown in this case.

**Comments** Oncogenic hypophosphataemic osteomalacia is a rarely reported clinical condition. It is a paraneoplastic syndrome in that the involved neoplasm is often of a limited clinical significance apart from its impact on the musculoskeletal system [1].

Tumours responsible for oncogenic osteomalacia are usually more benign rather than invasive, whereas the main clinical complaints of the patient is debilitating osteomalacia [2]. In some rare case, however, this condition has been reported in association with carcinomas [3]. It is similar to X-linked hypophosphatemia in pathogenesis of decreased mineralization of newly formed bone and the clinical findings of osteomalacia. However, oncogenic osteomalacia is an acquired phenotype, whereas x-linked hypophosphataemia tends to manifest during the second year of life. Patients with oncogenic osteomalacia also usually present with more fractures and more severe bone pain than those with x-linked hypophosphataemia [4]. The pathogenesis behind this condition is the excessive renal loss of phosphate [5]. PTH and serum calcium level are usually normal; however, mild hypocalcaemia has been described in some case. Elevations of serum alkaline phosphatase activity is typical. Low or normal circulating levels of 1, 25-dihydroxyvitamin D are observed, despite the stimulation of hypophosphataemia. Tumours often remain unidentified for years following the diagnosis of hypophosphataemic osteomalacia and the management in such cases is phosphate and calcitriol and long-term surveillance [4].

## References

1. Carpenter TO. New perspectives on the biology and treatment of X-linked hypophosphatemic rickets. *Pediatr Clin North Am.* 1997; 44:443-66.

2. Lee H, Sung W, Solodnik, Shimshi M. Bone Scan in Tumor-Induced Osteomalacia. J Nucl Med 1995; 36:247-249
3. Lyles KW, Berry WR, Haussler M, Herrelson JM, Drezner MK. Hypophosphataemic osteomalacia: association with prostatic carcinoma. Ann Intern Med 1980; 93:275-8.
4. Carpenter T. Oncogenic osteomalacia-a complex dance of factors. N Engl J Med 2003; 348:1705-8.
5. Fukomoto S, Takeuchi Y, Nagano A, Fujita T. Diagnostic utility of magnetic
6. resonance imaging skeletal survey in a patient with oncogenic osteomalacia. Bone 1999; 25:375-7.